

Loncastuximab Tesirine: Structure, Mechanism and Clinical Trial

Yanjie Sun*

Department of Medicine, Henan Vocational College of Nursing, Anyang, 455000, China

*Corresponding author: sunyanjie666@stu.ahu.edu.cn

Keywords: Loncastuximab tesirine, DLBCL, cancer, immunological therapy.

Abstract: A recent retrospective study found that the prognosis of some patients with relapsed/refractory DLBCL was poor. Its results indicate the emergent requirement for a new treatment. This review focused on the structure of loncastuximab tesirine and its mechanism, as well as phase I and phase II experimental studies in non-Hodgkin's lymphoma. The safety and efficacy of loncastuximab tesirine in DLBCL were analyzed. Efficacy data showed that loncastuximab tesirine was active in different types of non-Hodgkin's lymphoma, and phase II studies showed persistent responses, including high-risk subgroups. Loncastuximab tesirine will be an important supplement to the alternative therapy of DLBCL.

1. Introduction

Recent years, cancer has become a kind of troublesome disease, and its incidence has been at the top on the list for many years. People have spent decades exploring treatments for cancer, Initially, Nitrogen mustard was found to treat malignant lymphoma. Several years later, the Bio alkylating agent was discovered to act on DNA of cancer. With the development of Antimetabolic drug, they can affect the biosynthesis of nucleic acids in tumor cells. But these drugs have strong non-specific side effects, which are easily prone to drug resistance, and their treatment window is narrow [1]. It is estimated that there are 150,000 new cases of large b-cell lymphoma worldwide each year, which is the normal type of non-Hodgkin's lymphoma in adults, accounting for about 20%-50%. Diffuse large B-cell lymphoma (DLBCL) is a group of invasive malignant lymphomas with a median age of 65 years. More than half of DLBCL patients can use the standard R-CHOP regimen (rituximab, cyclophosphamide, doxorubicin, vincristine, prednisone), which has been in a first-line treatment for nearly 20 years, but about one fifth of patients will have standard R-CHOP regimen ineffective or relapse after 6 months of standard regimen treatment, which is "primary refractory after standard treatment", about one fourth of patients relapsed within 2 years of standard R-CHOP regimen, which is "early relapsed after standard treatment". Some patients have recurred after 2 years of treatment, which is "late relapsed after standard treatment" [2]. About half patients with relapsed /refractory DLBCL have response to second-line chemotherapy, 50% patients among them were eligible for autologous hematopoietic stem cell transplantation. Patients who can neither use high-dose chemotherapy nor take hematopoietic stem cell transplantation as second-line treatment have a poor prognosis, with a median overall survival rate of 4.4 months. One-year overall survival rate was 23%, while two-year overall survival rate was only 16%. Even the patients who can be transplanted are not yet optimistic and are easily accompanying with various complications [3].

A recent retrospective study found that the prognosis of primary refractory or relapsed DLBCL within 12 months after autologous hematopoietic stem cell transplantation was only poor. This study indicated the emergent requirement for a new treatment.

Therefore, as a breakthrough treatment, monoclonal antibody has been paid close attention to in the field of relapsed/refractory DLBCL because of its accurate specificity and slight side effects, and it is widely used in the treatment of various diseases. In particular, antibody-drug conjugate (ADC) is combined by the coupling of monoclonal antibodies and cytotoxic drugs, which can accurately provide cytotoxic warheads against cancer cells, minimize systemic toxicity and maximize the efficacy of killing tumors.

CD19 is a type I transmembrane glycoprotein of 95kD, which occupied an important position in the regulation of receptor signal pathway of B-cell, expressed in the whole process of b-cell maturation, but displayed more widely in the early growth stage of aggressive lymphoid cancer B-cell [4]. It was found in all kinds of B-cell malignant, including non-Hodgkin's lymphoma and B-cell-derived leukemia. The expression of CD19 is not as much as that of CD20, so that it can be internalized quickly in the process of antigen binding and will not leak into the cycle. In summary, CD19 has become a very attractive target for antibody-based therapy of B-cell malignant, widely used in the development of ADCs, monoclonal antibody and CAR-T therapy.

This review focused on a new approved drug: Loncastuximab tesirine (a kind of ADC targeting CD19), introduced its structure, mechanism and clinical trial. At the end of the article, other therapies of DLBCL and some thoughts on the development of Loncastuximab tesirine are described.

2. Structure

ADCs usually composed by monoclonal antibodies and cytotoxic warheads, monoclonal antibodies can target tumor and trigger a violent reaction by alkylation or anti-mitotic mechanism. Clinically, this powerful small molecular component attached to a chemical connector is called a warhead [4]. There are mainly two kinds of payloads: microtubule inhibitors (auristatins and maytansines) and DNA-interacting agents (calicheamicin, pyrrolobenzodiazepine dimers, duocarmycin, etc.). Its linkers are also sorted out cleavable and non-cleavable agents.

Loncastuximab tesirine (loncastuximab tesirine-lpyl; ZynllontaTM) is an antibody-drug conjugate (Figure 1). It is comprised of pyrrolobenzodiazepine (PBD) alkylated DNA warhead (SG3199) and valine-alanine protease cleavable linker (tesirine) conjugated to humanized anti-CD19 antibody [5].

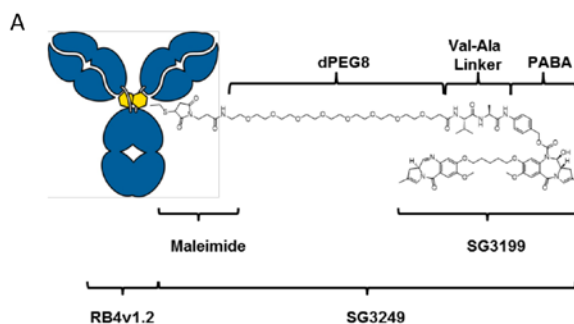


Figure 1 Structure of ADCT-402.

In the 1960s, anthramycin was discovered as the first member of the pyrrolobenzodiazepine (PBD) family of antitumor antibiotics [6]. The introduction of PBD dimer gives birth to ADC therapy: it developed cellular targets that are completely different from tubulin inhibitors and formed a new mode of DNA damage. In vitro experiments, SG3199, a PBD dimer, was significantly more effective in eradicating cancer stem cells than tubulin inhibitors monomethyl auristatin E(MMAE). In vivo experiments, it was found that ADCs containing SG3199 was more valid ADCs containing tubulin inhibitor in reducing the number of tumor stem cells [7].

3. Mechanism

The three parts of Loncastuximab tesirine: SG3199 warhead, valine-alanine protease cleavable linker, humanized anti-CD19 antibody, all played a unique and ingenious role in the mechanism of antineoplastic. First, humanized antibody conjugates recognized CD19⁺ tumor cells and selectively penetrated cancer cells, after the antibody binds to the CD19 receptor, the antibody-cd19 complex was rapidly internalized and isolated. (Figure 2) Then, the lysosome was activated and Loncastuximab tesirine's valine-alanine protease can cleave the ligand. Finally, lysosomal abolished and the residual linker stub released SG3199, lysosome was located in the val-ala dipeptide linker, while the residual linker stub was situated on the PBD N10 imine in tumor cells.

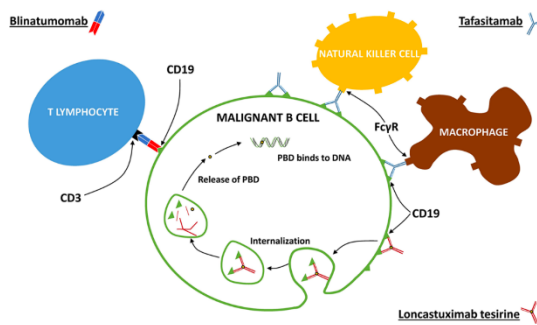


Figure 2 Three mechanisms of antibodies (targeting CD19)

Pyrralobenzodiazepine cross-linked the minor grooves interstrand of DNA, which produced the minimum distortion that made the interstrand joint of DNA more flexible and discrete. This kind of highly cytotoxic cross-linking enabled SG3199 to escape the repair mechanism of host DNA, which led to tumor cell apoptosis and improved the validity of this coupling. Simultaneously it was found that this feature could be persistent after 36 hours, which not only helped Loncastuximab tesirine affect the slow proliferation of target cells (including tumor initiation cells or cancer stem cells) but also ensured that tumor cells were continuously killed and prevented tumor relapsed, so as to achieve the purpose of accurately eradicating cancer. Compared with other tubulin inhibitor antibodies against CD19, it shows more excellent biological anti-tumor activity and intracellular persistence (Hartley 2020; Duell et al. 2019; Cheson et al. 2021). Soluble SG3199 warhead had a global effect on tumor cells: both CD19 positive and negative cell lines were highly sensitive to SG3199. The non-selective penetration of SG3199 enabled it to act on heterogeneous tumors of neighboring CD19- cells as well, which induced “Bystander Effect” and led to cell death. “Bystanders Effect” means antibodies of antibody-drug conjugate targeted binding to the surface antigens of tumor cell, then ADC was swallowed into the cell, released the conjugated cytotoxic drugs, caused cancer cells dying and getting lysed. Cytotoxic drugs were released into the surrounding environment, its non-selective destruction could kill cancer surrounding cells, regardless of the corresponding antigen cell was positive or negative. Therefore, the patients could benefit from bystander killing of surrounding CD19-negative tumor cells [4].

4. Clinical efficiency

At present, the research group has conducted two phases ' trials on Loncastuximab tesirine:

4.1. Phase I trial (NCT026669017)

This trial consists of two parts: dose increment and dose expansion, 183 patients with relapsed/refractory B-NHL were selected from 11 medical centers in many countries, relapsed/refractory large B-cell lymphoma accounted for 76%, mantle cell lymphoma accounted for 8.2%, follicular lymphoma accounted for 7.5%, and other subtypes accounted for 8%. The median age of these patients was 63 years, with a number of males accounting for 62% [8].

(1) Part I dose increment

To evaluate the safety of Loncastuximab tesirine during treatment and to determine the MTD (maximum tolerable dose) and recommended dilution dose of Loncastuximab tesirine, 88 patients with relapsed/refractory B-NHL were treated monotherapy with Loncastuximab tesirine with a dose range of 15 - 200 $\mu\text{g} / \text{kg}$. Loncastuximab tesirine was injected intravenously for more than one hour on the first day of every three weeks, and the experiment was designed according to the increasing dose of 3 + 3 [9]. Starting from the initial Dose, there are 3 subjects at each Dose level, if no DLT (dose-limiting toxicity) is present, the experiment will proceed to the next Dose, if 1 DLT, it will add 3 subjects at that Dose, if ≥ 2 DLT, then the prior dose is MTD.

The results showed that Loncastuximab tesirine had good clinical activity and acceptable safety, the maximum tolerated dose was not reached, and 150 μ g/kg was recommended for the further study of the second part. All patients experienced treatment-emergent adverse events (TEAE), the common of which were neutropenia, thrombocytopenia, anemia, fatigue, edema, nausea, rash, dyspnea and elevated GGT (gamma glutamine transferase). Most of patients with B-NHL experienced grade 3 emergency adverse events, one third patients experienced severe situation, and the less than 10 patients reached a fatal level. Some subjects were stopped because of emergency adverse events, some patients were reduced or postponed because of emergency adverse events, the most obvious cumulative dose of drug toxicity was 200 μ g / kg, and most patients could endure more than two courses of treatment at full dose. One patient had febrile neutropenia at 150 μ g / kg, and two patients had grade 4 thrombocytopenia at 200 μ g / kg, the results of the first part found that in terms of clinical efficacy was as follows: around 85 patients participated in the post-treatment evaluation, approximately 50 cases found tumor fade, roughly 40 cases were relieved, 28 cases obtained complete response and 13 cases obtained partial response. The median progression-free survival was 4.8, the duration of response was 5.5, and the overall survival time was 11.6 months [9].

(2) Part I dose increment

To study the problem of "evaluating the safety of the recommended dose of 150 μ g / kg in the first part of the experimental results", the experimental method adopted by the research group was as follows: 26 patients were given a dose of 120 μ g/kg (Q3W) + 150 μ g / kg (Q3W) (Part1+2: n=42), and 69 patients were given a dose of 150 μ g /kg of loncastuximab tesirine, which was reduced to 75 μ g / kg Q3W later (Part1+2: n=88). The results showed that the recommended dose at this stage was 150 μ g / kg (Q3W) for 2 cycles, followed by 75 μ g / kg (Q3W). When analyzing the results of the experiment, the data of the patients participating in the first part were pulsed [8]. The data analysis settings were: Safety analysis set (n=183), DLT analysis set (n=73), Efficacy analysis set (n=180). The results showed that the TEAEs of the second part was consisted with that reported in the first part, which was the most obvious at 200 μ g /kg, but dexamethasone was added before the treatment of this part, and spironolactone was used to control the adverse reactions. At the dose of 120 μ g / kg, dexamethasone reduced the incidence of edema and effusion in the first part from 68.8% to 34.6%. Dexamethasone reduced the incidence of edema and effusion compared with the first part at a dose of 150 μ g/kg. And it pointed out the effect of sunlight on the rash. In terms of clinical efficacy was as follows: the ORR of B-NHL patients was 45.6%, CRs was 26.7% and PRs was 18.9%. The ORR at 120-200 μ g / kg dose was 47.2%, while the ORR at 15-90 μ g / kg dose was 29.4%. The median time for tumor remission in patients was 43 days (range 31-323 days), and the optimal percentage change in tumor size compared with the baseline is shown in the dose and histology of figure 3, the median DOR of patients using loncastuximab tesirine was 5.4 months. Through two experiments in Phase I, the research group found that loncastuximab tesirine has acceptable safety and significant anti-tumor activity [8].

4.2. Phase II trial NCT03589469

The purpose of the phase II trial is evaluated the safety and anti-tumor activity of loncastuximab tesirine in patients with R/R large B-cell lymphoma. The methods adopted by our team were as follows: 145 patients with relapsed or refractory DLBCL were treated with more than two kinds of multidrug therapy in 28 hospitals in the United States, Britain, Italy and Switzerland [10]. On the first day of each 21-day cycle, subjects were required to receive intravenous injection for more than 30 minutes at a dose of 150 μ g / kg for 2 cycles, then 75 μ g/ kg for 1 year, and oral dexamethasone before administration, due to the light-sensitive rash in the first phase of the study, skin exposure to sunlight was strictly controlled, patients with weight-gaining of more than 1 kg from the first day of the first cycle and patients with edema or pleural effusion need to be treated with spironolactone [10]. The study show that Loncastuximab tesirine has obvious anti-tumor activity and has a long-lasting effect while ensuring safety [10]. As for the safety of Loncastuximab tesirine, most of the adverse reactions were caused by pyrrolbenzodiazepine, after using standard spironolactone, dexamethasone and more strict sunshine advice, the incidence of elevated liver enzymes, rash and fluid retention was similar or less than that of the first phase of the study. Pyrrolbenzodiazepine-related adverse events were mostly

mild to moderate and usually could be reversed and controlled, it was found that 70 of the 145 patients were in complete or partial response (ORR was 48.3%), both the complete response (CR) and partial response (PR) were 24%, the most common grade 3 TEAEs were thrombocytopenia (26 cases, 18%), neutropenia (37 cases, 26%) and elevated γ -glutamyl transferase (24 cases, 17%), 57 cases (39%) reported serious adverse events. 8 cases (6%) had emergency adverse events with fatal outcome, all of adverse events were not considered to be related to loncastuximab tesirine. The median time to the first reaction was 1.3 months, the median PFS was 4.9 months, the OS was 9.9 months and the relapse-free survival time (RFS) was 13.4 months. The median remission time of CR patients was 13.4 months, while that of PR patients was 5.7 months. No anti-Zynlonta antibody was detected in 134 patients who took Zynlonta at the recommended dose (Caimi et al., 2021).

5. Alternative treatment of dlbc1

In recent years, the treatment of R / R DLBCL has been greatly developed, providing these patients with more options. The recent treatment is as follows:

CAR-T (Chimeric Antigen receptor T cells) is not suitable for patients with rapidly deteriorating and frail, but it is good for patients in chemorefractory DLBCL who can tolerate the side effects of CAR-T and wait for the production cycle of CAR-T, and CAR-T was observed a more prominent efficacy and applicability than rescue therapy after autologous stem cell transplantation. Preliminary results have shown that the patients can be relieved after the therapy of CAR-T, but this will need prospective study, and the role of targeting CD19 repetitive therapy also requires further defined [2].

POLARIX, phase III clinical study showed that targeted CD79 antibody-drug conjugate Polatuzumab vedotin (Pola) combined with R-CHP regimen has remarkably improved progression-free survival compared with R-CHOP, the current standard treatment in the field of diffuse large B-cell lymphoma. (NCT03274492), Pola-R-CHP regimen significantly reduced the risk of disease progression, relapsed or death compared with R-CHOP regimen [11]. However, this does not conflict with Loncastuximab's research and development prospects, because the two drugs have different targets, safety and payloads.

Polatuzumab plus bendamustine-rituximab and Tafasitamab plus lenalidomide, these two combinations were evaluated and found that they were an alternative treatment for subjects who had received more than one systematic treatment and were not eligible for CAR-T cell therapy or autologous stem cell transplantation. However, the effect of these two combination treatments is not clear for patients with transformed, primary refractory and highgrade [12].

Loncastuximab combined with venetoclax, ibrutinib, PI3 kinase inhibitor and bendamustine. Studies have shown synergistic activity in vitro researches. When Loncastuximab was used combination, the combination can effectively control the disease and improve the efficacy [12].

Some new drugs, such as ADCs targeting CD37, Bites targeting CD3/CD20 (glofitamab, odronextamab, and epcoritamab) and chimeric antigen receptor T cells and NK cells, pose a threat to the future research and development of Loncastuximab.

6. Limitation and challenge

Through the analysis of the clinical results of phase I and phase II of loncastuximab, it is found that the drug is not appropriate for patients with the risk of complications of excessive body fluid, patients who cannot avoid sunlight exposure, and patients with overweight, but it can be used as a valuable supplementary salvage scheme for the treatment of DLBCL. In particular, the long-lasting efficacy shown in the risk subgroup makes it a program for a variety of relapsed / refractory DLBCL, which include transformed indolent lymphoma, peripheral neuropathy, and high-grade B-cell lymphoma. With the appearance of many treatments for DLBCL and other B-cell malignancies. It is predicted that the challenge of Loncastuximab is rapid development and change of the present and future competitive therapies.

7. Conclusion

Loncastuximab tesirine is an antibody-drug coupling compound, which ingeniously combines the accuracy of immune response with traditional chemotherapeutic drugs. It generated maximal efficacy on the base of minimal side effects. The antibody part of Loncastuximab tesirine bind to CD19, allowing Loncastuximab tesirine to be internalized and releasing SG3199. This kind of warhead then binds to the DNA microgroove, which made the host DNA repair mechanism not to recognize, and Loncastuximab tesirine can holding long-lasting efficacy. Clinical experimental studies have shown that loncastuximab tesirine is safe, and the main adverse events are hematological adverse events, fluid overload and elevated GGT. The recommended dose is 150 μ g / kg, Q3W for two cycles and 75 μ g / kg, Q3W for the second time. ADCT-402 is a good choice for relapsed/ refractory diffuse large B-cell lymphoma. In the future, in order to have a place in the treatment of R / R DLBCL, research on this field should mainly observe its efficacy in patients who are no response after receiving CAR-T cells, tafaitamab or polatuzumab. Focused studies will include determining the role of Loncastuximab in earlier lines and in combination

References

- [1] Sehn, L. H., & Salles, G. (2021). Diffuse Large B-Cell Lymphoma. *New England Journal of Medicine*, 384(9), 842–858.
- [2] Logue, J. M., & Chavez, J. C. (2021). How to Sequence Therapies in Diffuse Large B-Cell Lymphoma Post-CAR-T Cell Failure. *Current Treatment Options in Oncology*, 22(12), 112.
- [3] Susanibar-Adaniya, S., & Barta, S. K. (2021). 2021 Update on Diffuse large B cell lymphoma: A review of current data and potential applications on risk stratification and management. *American Journal of Hematology*, 96(5), 617–629.
- [4] Chu, Y., Zhou, X., & Wang, X. (2021). Antibody-drug conjugates for the treatment of lymphoma: Clinical advances and latest progress. *Journal of Hematology & Oncology*, 14(1), 88.
- [5] Lee, A. (2021). Loncastuximab Tesirine: First Approval. *Drugs*, 81(10), 1229–1233.
- [6] Hartley, J. A. (2021). Antibody-drug conjugates (ADCs) delivering pyrrolobenzodiazepine (PBD) dimers for cancer therapy. *Expert Opinion on Biological Therapy*, 21(7), 931–943.
- [7] Zammarchi, F., Corbett, S., Adams, L., Tyrer, P. C., Kiakos, K., Janghra, N., Marafioti, T., Britten, C. E., Havenith, C. E. G., Chivers, S., D’Hooge, F., Williams, D. G., Tiberghien, A., Howard, P. W., Hartley, J. A., & van Berkel, P. H. (2018). ADCT-402, a PBD dimer-containing antibody drug conjugate targeting CD19-expressing malignancies. *Blood*, 131(10), 1094–1105.
- [8] Hamadani, M., Radford, J., Carlo-Stella, C., Caimi, P. F., Reid, E., O’Connor, O. A., Feingold, J. M., Ardesna, K. M., Townsend, W., Solh, M., Heffner, L. T., Ungar, D., Wang, L., Boni, J., Havenith, K., Qin, Y., & Kahl, B. S. (2021). Final results of a phase 1 study of loncastuximab tesirine in relapsed/refractory B-cell non-Hodgkin lymphoma. *Blood*, 137(19), 2634–2645.
- [9] Kahl, B. S., Hamadani, M., Radford, J., Carlo-Stella, C., Caimi, P., Reid, E., Feingold, J. M., Ardesna, K. M., Solh, M., Heffner, L. T., Ungar, D., He, S., Boni, J., Havenith, K., & O’Connor, O. A. (2019). A Phase I Study of ADCT-402 (Loncastuximab Tesirine), a Novel Pyrrolobenzodiazepine-Based Antibody–Drug Conjugate, in Relapsed/Refractory B-Cell Non-Hodgkin Lymphoma. *Clinical Cancer Research*, 25(23), 6986–6994.
- [10] Caimi, P. F., Ai, W., Alderuccio, J. P., Ardesna, K. M., Hamadani, M., Hess, B., Kahl, B. S., Radford, J., Solh, M., Stathis, A., Zinzani, P. L., Havenith, K., Feingold, J., He, S., Qin, Y., Ungar, D., Zhang, X., & Carlo-Stella, C. (2021). Loncastuximab tesirine in relapsed or refractory diffuse large B-cell lymphoma (LOTIS-2): A multicentre, open-label, single-arm, phase 2 trial. *The Lancet Oncology*, 22(6), 790–800.

[11] Tilly, H., Morschhauser, F., Sehn, L. H., Friedberg, J. W., Trněný, M., Sharman, J. P., Herbaux, C., Burke, J. M., Matasar, M., Rai, S., Izutsu, K., Mehta-Shah, N., Oberic, L., Chauchet, A., Jurczak, W., Song, Y., Greil, R., Mykhalska, L., Bergua-Burgués, J. M., Cheung, M. C., ... Salles, G. (2022). Polatuzumab Vedotin in Previously Untreated Diffuse Large B-Cell Lymphoma. *The New England journal of medicine*, 386(4), 351–363.

[12] Goparaju, K., & Caimi, P. F. (2021). Loncastuximab tesirine for treatment of relapsed or refractory diffuse large B cell lymphoma. *Expert Opinion on Biological Therapy*, 21(11), 1373–1381.